

Arthroscopic Management of the Painful Snapping Scapula

Eiyiyemi O. Pearse, M.A., F.R.C.S.(Orth), Juan Bruguera, M.D.,
Samir N. Massoud, F.R.C.S.I.(Orth), Giuseppe Sforza, M.D., Stephen A. Copeland, F.R.C.S.,
and Ofer Levy, M.D., M.Ch.(Orth)

Purpose: The aim of this study was to evaluate the results of the arthroscopic management of the snapping scapula syndrome. **Type of Study:** Case series. **Methods:** Thirteen patients underwent surgery for painful scapular snapping that had not responded to adequate conservative treatment. They had no evidence of anatomic abnormalities on plain radiographs. All patients underwent bursectomy and resection of bands of fibrous tissue at the superomedial angle. Bone was resected from the superomedial angle only if it appeared to be prominent during arthroscopy. This occurred in 3 cases. The patients' outcomes were assessed subjectively by their ability to return to work and their return to leisure, as well as the Constant score. **Results:** At the time of follow-up, 9 patients (69%) reported an improvement in their symptoms. Their median Constant score was 87 (range, 95 to 58). Four patients felt that their symptoms were unchanged or worse. Their median Constant score was 55 (range, 66 to 32). Of 9 employed patients, 8 returned to their previous careers. This group included 2 patients with physically demanding jobs. Of 9 patients who played sports regularly, 6 returned to their presymptomatic level of sporting activity. There were no complications. **Conclusions:** Subscapular bursectomy is a safe procedure with a low rate of morbidity. In the absence of a definable anatomic abnormality, arthroscopic bursectomy for the painful snapping scapula can result in satisfactory outcomes in approximately 70% of patients. More clearly defined indications for and contraindications against surgery are required to avoid poor results. Complete resolution of the snapping in the subscapular bursa is not necessary to obtain a satisfactory result. **Level of Evidence:** Level IV, case series, no control group. **Key Words:** Snapping scapula—Arthroscopy—Bursectomy.

The snapping scapula syndrome is a rare cause of shoulder pain. Patients fall into 1 of 2 categories: those with a radiologically identifiable anatomic abnormality and those without such an abnormality. Patients with definable abnormalities such as scapular exostosis, osteochondroma, and Luschka's tubercle require surgical resection of the lesion for resolution of symptoms.^{1,2}

When there is no evidence of an anatomic abnormality, the cause of the snapping is poorly understood.

Most cases respond to conservative management.³ This consists of physiotherapy and injections of local anesthetics and steroids. Operative intervention is indicated when patients do not respond to conservative measures. Successful outcomes have been reported with several open procedures. These include musculoplasty,⁴ bursectomy,^{5,6} open resection of the medial border of the scapula,⁷ and open resection of the superomedial angle of the scapula.^{2,8,9} More recently, an arthroscopic approach for this problem has been described. Although the experience is limited, satisfactory results have been reported with bursectomy and resection of the superomedial angle of the scapula by a number of authors.¹⁰⁻¹²

Our hypothesis was that arthroscopic bursectomy and selective resection of the superomedial angle of the scapula could resolve the symptoms of the painful snapping scapula in patients who do not respond to conservative treatment. The aim of this study was to

From the Reading Shoulder Unit, Royal Berkshire Hospital (E.O.P., S.N.M., G.S., S.A.C., O.L.), Reading, England; and Hospital San Juan de Dios (J.B.), Pamplona, Spain.

Address correspondence and reprint requests to Eiyiyemi O. Pearse, M.A., F.R.C.S.(Orth), 28 Elm Grove Rd, Barnes, London SW13 0BT, England. E-mail: YemiPearse@aol.com

*© 2006 by the Arthroscopy Association of North America
0749-8063/06/2207-4353\$32.00/0
doi:10.1016/j.arthro.2006.04.079*

evaluate the results of the arthroscopic management of the snapping scapula syndrome.

METHODS

Thoracoscaphular arthroscopy was first performed at the Reading Shoulder Unit, Reading, England, in February 1996 by 2 of the senior authors (S.A.C. and O.L.). A third surgeon (J.B.) gained experience in thoracoscaphular arthroscopy during his fellowship at the Reading Shoulder Unit and now operates independently at the Hospital San Juan de Dios, Pamplona, Spain.

All patients who underwent thoracoscaphular arthroscopy at either institution between February 1996 and October 1999 were included. They were identified from a database of all operative procedures performed at both institutions.

We obtained preoperative, operative, and postoperative details retrospectively from hospital records. All patients were seen in the clinic within 6 weeks of their operations. Further clinic reviews were arranged as indicated. For final follow-up, patients were invited to attend for clinical review. Because of the complex

referral pattern to the Reading Shoulder Unit, few patients lived locally and most were unable to attend. Those who were not able to attend were assessed by carefully designed postal questionnaires and telephone interviews.

Outcome measures were overall subjective improvement, pain level, and change in activity level (occupation and sports). There is no established outcome scoring system for this condition. We elected to use the Constant score.¹³ Despite careful review of the medical and physiotherapy records of each patient, it was not possible to determine preoperative scores reliably.

Operative Technique

All operations were performed with the patients under a general anesthetic. Patients were placed in the lateral position with the arm free. A stab incision was made at the junction of the lower and middle thirds of the scapula 3 to 4 cm medial to the vertebral border. This avoided injury to the dorsal scapular nerve and artery (Fig 1A) and prevented perpendicular orientation of the arthroscope to the chest wall. A sheathed

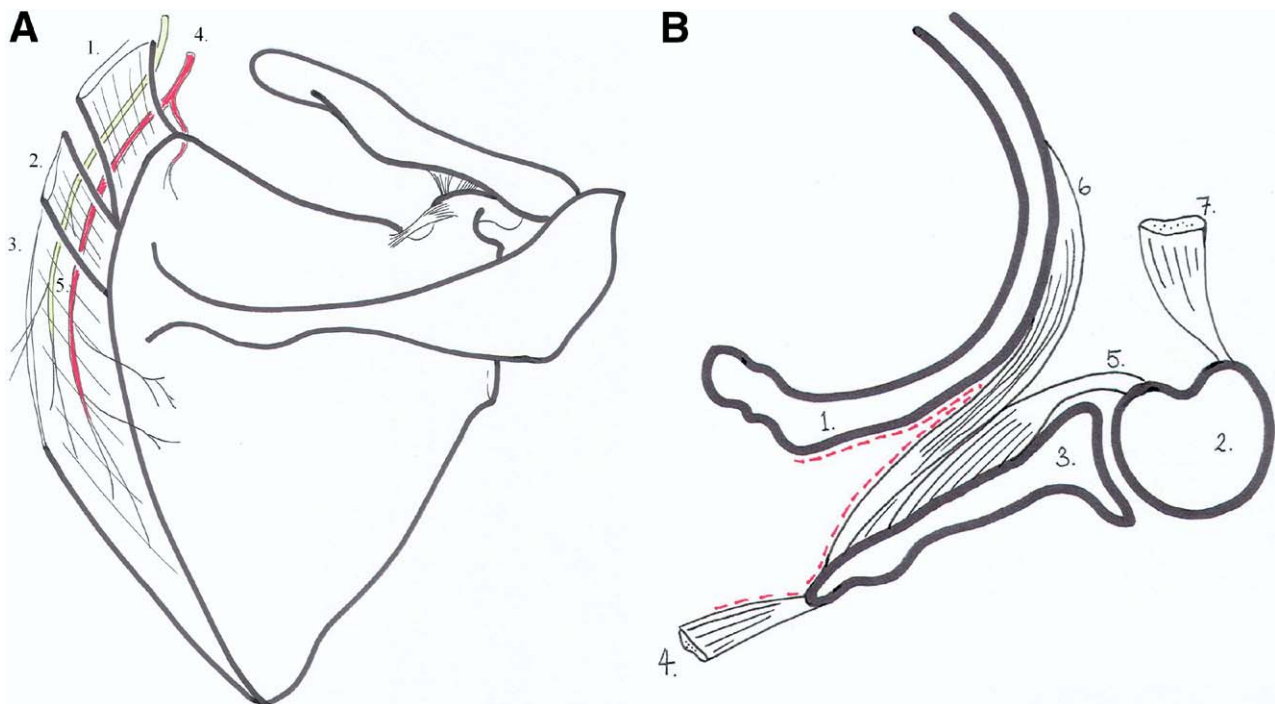


FIGURE 1. (A) Axial section of scapulothoracic articulation: the ribs, serratus anterior, medial edge of the scapula, and rhomboid major form the boundaries of the serratus anterior space. (1, rib; 2, humerus; 3, scapula; 4, rhomboid major cut and reflected; 5, subscapularis; 6, serratus anterior; 7, pectoralis major cut.) (B) Relevant anatomy of medial border of scapula. (1, levator scapulae; 2, rhomboid minor; 3, rhomboid major; 4, transverse cervical artery; 5, dorsal scapular nerve and artery.)

blunt introducer was passed through the skin, subcutaneous tissue, and trapezius and rhomboid major into the serratus anterior space. The introducer was withdrawn, and a standard 4.5-mm 30° arthroscope was introduced into the serratus anterior space (Fig 1B). This was attached to a monitor and mechanical pump-driven fluid management system. The fluid pressure was kept low, at 50 mm Hg. The bursa was examined. It was sometimes necessary to debride the loose areolar tissue within the bursa to obtain a satisfactory view. This was achieved with a shaver, which was also introduced 3 to 4 cm medial to the vertebral border of the scapula below the level of the spine (Fig 2).

The decision as to whether to resect the superomedial angle of the scapula was made intraoperatively. It was based on the subjective visual assessment of the operating surgeon: the superomedial angle was resected if it appeared to be prominent. In addition, the space was temporarily deflated and the arm moved to determine whether this area impinged on the deeper structures. In all cases bands of fibrous tissue were found at the superomedial angle and resected with the shaver (Fig 3). At the end of the procedure, as much fluid was removed from the space as possible, the wounds were dressed, and the patient's shoulder was placed in a sling for 48 hours and then mobilized with active physiotherapy.

RESULTS

Thirteen patients underwent thoracoscapular arthroscopy between February 1996 and October 1999.

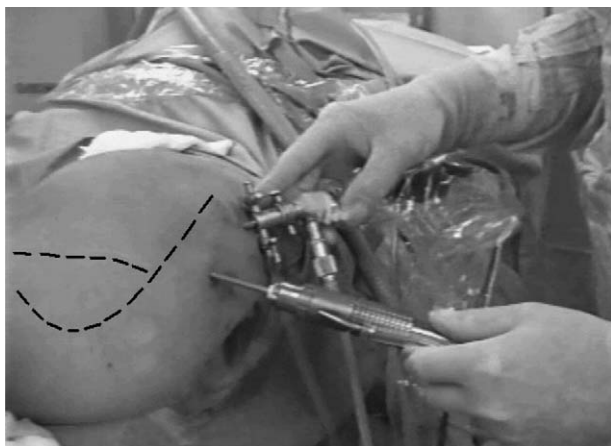


FIGURE 2. Operative technique. Both portals are made 3 to 4 cm medial to the vertebral border of the scapula below the level of the spine. The broken lines indicate the positions of the vertebral border of the scapula, the superomedial angle, and the spine of the scapula.

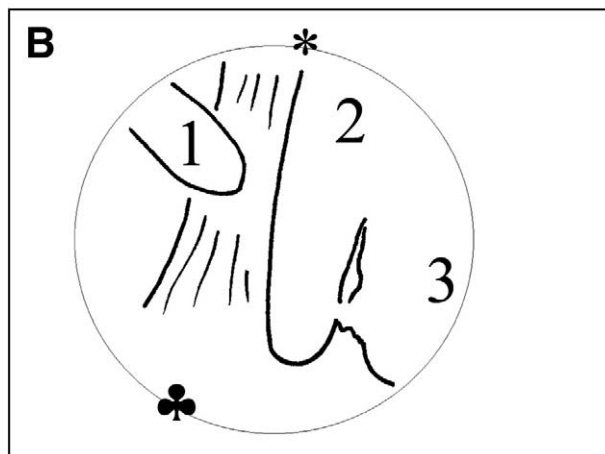
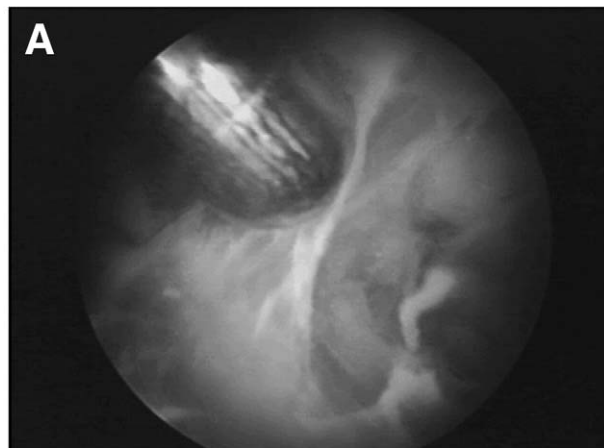


FIGURE 3. (A) Intraoperative photograph showing dense fibrous tissue at superomedial angle of scapula. (B) Annotated line drawing of 3A. The asterisk indicates the scapula, and the club symbol indicates the chest wall. (1, shaver; 2, dense fibrous band; 3, resected fibrous band.)

There were 7 men and 6 women with a mean age of 35 years (range, 18 to 52 years).

All patients complained of pain at the superomedial angle of the scapula. They all had demonstrable scapular snapping that was variably described as clicking, crepitus, crunching, cracking, and grating and associated with significant pain with activity. The symptoms had been present for a mean of 6.8 years (range, 1.5 to 30 years) before surgery.

Of the patients, 6 reported a history of trauma at the onset of their symptoms: 2 had fallen onto their shoulders, 1 had injured the shoulder while skiing, 1 had injured the shoulder while playing rugby, 1 had injured the shoulder while playing football, and 1 had injured the shoulder as the driver in a car accident.

One patient had previously undergone scalenotomy for thoracic outlet syndrome. Two patients had previously undergone glenohumeral arthroscopy and subacromial decompression for presumed impingement, although it was noted at bursoscopy that there was no significant impingement lesion in either case.

All patients had clinically normal glenohumeral and acromioclavicular joints. A full range of shoulder movement was noted in each case. Pain and snapping were reproduced with shoulder movement but not with isometric contraction of the rhomboid or trapezius muscles or the levator muscles of the scapula. Three patients were noted to have mild scapular winging thought to be a result of the painful thoracoscapular dysfunction. One patient had a thoracic scoliosis.

All patients did not respond to conservative treatment consisting of nonsteroidal anti-inflammatory medicines, 2 injections of local anesthetics and steroids into the superomedial angle of the scapula, and physiotherapy by an experienced shoulder physiotherapist. All patients had some improvement in their pain after the injections. The exact duration of symptom relief was poorly documented. The mean duration of physiotherapy was 13.5 months (range, 9 to 15 months).

All patients had normal radiographs including tangential views of the symptomatic scapula. Computed tomography (CT) scans were performed in only 3 cases and did not show any bony or soft-tissue abnormality related to the scapula.

Patients were seen in the clinic a mean of 3.5 times (range, 1 to 5 times) before a decision was made to perform surgical intervention. Three surgeons (S.A.C., O.L., and J.B.) performed all procedures. Ten patients

underwent bursectomy and division of dense fibrous adhesions only. Three patients underwent bursectomy, division of dense fibrous adhesions, and resection of the superomedial angle of the scapula. There were no postoperative complications. A summary of the patient profiles is given in Table 1.

All patients were seen postoperatively in the clinic within 6 weeks of their operations. At the first postoperative review, they all reported a subjective improvement in their pain and snapping.

At the final review, 5 patients were available for clinical review. Eight patients were reviewed by postal questionnaire and telephone interview. Of the patients, 9 (69%) reported an improvement in their symptoms. Of these, 6 rated their postoperative symptoms as "much better" when compared with their preoperative symptoms and were completely pain-free. Their median Constant score was 88 (range, 80 to 95). Three rated their postoperative symptoms as "better" but had moderate pain. Their median Constant score was 84 (range, 58 to 88).

Four patients reported no improvement after their operations. Three of these rated their postoperative symptoms as "the same": one had mild pain, two had moderate pain, and their median Constant score was 59 (range, 52 to 66). One patient rated his symptoms as "worse." He described his pain as severe, and his Constant score was 32.

Of the 13 patients, 9 were employed before the onset of their symptoms. Three of the remaining four patients were students, and one was unemployed. Of the 9 employed patients, 8 returned to their previous careers. This group included 2 patients with physically

TABLE 1. Demographic and Clinical Details of Patients Who Underwent Arthroscopic Surgery for Painful Snapping Scapula

Patient No. (Significant History/Examination)	Age (yr)	Sex	Occupation	Length of Preceding Symptoms (yr)	History of Trauma
1	50	M	Salesman	4	Yes (fall)
2	47	M	Banker	1.5	Yes (skiing)
3 (subacromial decompression)	36	F	Secretary	25	No
4	21	M	Student	1	Yes (football)
5	26	F	Student	2	No
6	33	F	Shop assistant	2	No
7	35	M	Bricklayer	4	Yes (fall)
8	40	M	Army	3	Yes (car accident)
9 (scalenotomy, subacromial decompression, winging)	45	F	Supermarket checker	1.5	No
10 (thoracic scoliosis)	21	F	Student	6	No
11 (winging)	52	M	Research scientist	30	Yes (rugby)
12 (winging)	18	F	Student	5	No
13	32	M	Unemployed	3	No

demanding jobs: one was a soldier in the army, and the other was a bricklayer.

None of the patients were professional athletes, but 9 were involved in regular recreational sport activities before the development of their symptoms. Six returned to their presymptomatic level of sporting activity.

All patients reported persistent snapping at final review, but it was not as loud as it had been preoperatively and was not painful or was mildly painful in 7 of 13 cases.

The outcomes after surgery, including the constituent parts of the Constant score for each patient, are summarized in Table 2.

DISCUSSION

In the absence of a radiologically definable lesion, surgical treatment for painful snapping scapula syndrome is indicated when symptoms persist despite adequate conservative measures. Arthroscopic surgery has been shown to improve symptoms in up to 100% of such patients.¹⁰⁻¹² In our unit 69% of patients reported an improvement in their symptoms. We considered the possible reasons why surgery failed to improve symptoms in some of our patients.

Significant anatomic lesions, such as osteochondromas, exostoses, Luschka's tubercle, and malunited scapula or rib fractures, were identified on plain radiographs, excluded from this series, and dealt with by open surgery. Abnormal anterior angulation of the scapula, resulting in scapulothoracic incongruity, is less readily identified with plain radiographs. Richards and McKee⁸ identified scapulothoracic incongruity in 2 patients with the snapping scapula syndrome by use of CT scans. No abnormalities were seen on plain radiographs. We performed CT scans on 3 of our patients and identified no incongruity. Mozes et al.¹⁴ reported that 3-dimensional CT reconstruction was more sensitive than plain radiography and CT for the detection of scapulothoracic incongruity. We did not use 3-dimensional CT reconstruction. The etiologic role of excessive anterior angulation of the scapula and the resultant scapulothoracic incongruity is unproven. There are no studies that compare scapulothoracic congruity of symptomatic and asymptomatic patients by use of CT scans. In addition, Edelson¹⁵ found excessive anterior angulation of the supraspinatus portion of the scapula in 8.5% of cadaveric specimens, but the snapping scapula syndrome clearly does not affect 8.5% of the population.

TABLE 2. Operative Procedures Performed and Postoperative Results of Patients Who Underwent Arthroscopic Surgery for Painful Snapping Scapula

Patient No. (Surgeon)	Procedure	Follow-up (mo)	Result	Pain	Activity Level			Postoperative Constant Score			
					Occupation	Sport	Pain (out of 15)	Activity (out of 20)	Range (out of 40)	Power (out of 25)	Total (out of 100)
1 (S.A.C.)	Bursectomy and shaving superomedial angle	16	Much better	None	Same	Same	15	20	40	20	95
2 (O.L.)	Bursectomy and excision of calcification	9	Much better	None	Same	Same	15	20	40	20	95
3 (O.L.)	Bursectomy	12	Much better	None	Same	Same	14	18	36	12	80
4 (J.B.)	Bursectomy	18	Much better	None	Same	Same	15	20	40	14	89
5 (J.B.)	Bursectomy	15	Much better	None	Same	Same	15	20	40	12	87
6 (J.B.)	Bursectomy	12	Much better	None	Same	None	14	16	40	16	86
7 (J.B.)	Bursectomy and shaving superomedial angle	12	Better	Moderate	Same	None	10	16	40	18	84
8 (J.B.)	Bursectomy	12	Better	Moderate	Same	Same	10	18	40	20	88
9 (O.L.)	Bursectomy	12	Better	Moderate	Decreased	None	6	12	38	2	58
10 (S.A.C.)	Bursectomy	52	Same	Mild	Same	Decreased	10	14	40	2	66
11 (O.L.)	Bursectomy and shaving superomedial angle	13	Same	Moderate	Same	Decreased	4	8	36	11	59
12 (S.A.C.)	Bursectomy	21	Same	Moderate	Same	Same	4	8	36	4	52
13 (S.A.C.)	Bursectomy	36	Worse	Severe	None	None	2	6	16	8	32

Another possibility was that we failed to resect the superomedial angle of the scapula when we should have. The reported results of bursectomy alone are variable.^{5,6,16} Of the 4 patients who reported no improvement in their symptoms, 3 had bursectomy alone. Our approach was to perform bursectomy and resect the superomedial angle only if it appeared prominent on visual inspection. The reported results of empiric resection of the superomedial angle of the scapula are better than the results we obtained with selective resection. It may be that visual inspection alone is far too subjective and is not sufficient to determine whether the superomedial angle is prominent. Of the 9 successful outcomes in our series, 8 were obtained with bursectomy alone, and empiric resection of the superomedial angle would have been unnecessary in these patients. However, arthroscopic resection has a low rate of morbidity,^{3,11} and Pavlik et al.¹¹ suggested that use of the superior portal, as described by Chan et al.,¹⁷ may allow better visualization and aid in the resection of the superomedial angle of the scapula.

A further possibility was that our failures were a result of patient selection. Our worst result was in an unemployed, alcoholic intravenous drug user. In our series he was the only patient who was either an alcoholic patient or an intravenous drug user. Scapulothoracic crepitus is not necessarily painful: it is claimed that Codman was able to make his own scapula "sound around the room without the slightest pain."¹⁸ Patients with the potential for secondary gain or psychiatric conditions may exaggerate their symptoms or may not respond to treatment. Three other patients reported no improvement in their symptoms. One patient had a thoracic scoliosis, and she underwent arthroscopic bursectomy. Although the snapping scapula syndrome has been reported in patients with scoliosis,¹⁹ the outcome in such cases is uncertain. Two patients were noted to have a degree of scapula winging. This may have been related to a C6/C7 disk prolapse impinging on the C7 nerve root in one of them. The exact cause of the winging was uncertain because neurophysiologic studies were not performed. Other investigators have reported good outcomes with surgery in patients with winging of the scapula.^{10,17} Our results suggest that these patients may have fewer good results.

A final possibility is that of incorrect diagnosis. This must be a consideration in the patient who had a C7 radiculopathy; however, pain would have been felt in either the C7 myotome or the C7 dermatome and not the superomedial angle of the scapula.

Study Limitations

This is a retrospective study and has the associated limitations, such as incomplete data and lack of standardization of protocols. There are no universally accepted indications or contraindications for surgery, and most authors report painful snapping that fails to respond to conservative measures. Our results suggest that better-defined surgical indications and contraindications are required. These are not evident from the literature because universally good results seem to be reported. Our results suggest caution in patients with undiagnosed winging or chest wall asymmetry and patients with concomitant cervical disease.

The number of patients in this study, though comparable to other published series, is small. As a result, it is not possible to reach statistically significant conclusions about the importance of winging or fixed chest wall asymmetry, which our results suggest may be related to poorer outcomes. Similarly, a history of trauma at the onset of symptoms appears to be a good prognostic indicator for surgery; however, multivariate analysis failed to identify this as a significant factor given the number of variables.

A final limitation is that fewer than half of the patients were reviewed clinically. As stated previously, because of a complex referral pattern, most patients were not local and were unwilling to travel significant distances for review. By designing a detailed questionnaire and following this up with telephone interviews, we were able to obtain reliable follow-up information.

CONCLUSIONS

Arthroscopic subscapular bursectomy and selective resection of the superomedial pole of the scapula comprise a safe procedure with a low rate of morbidity. In the absence of a definable anatomic abnormality this approach for the treatment of painful snapping scapula can result in satisfactory outcomes in approximately 70% of patients. In our experience, in this difficult group of patients, more clearly defined indications and contraindications are required to avoid poor results. The complete resolution of the snapping in the subscapular bursa is not necessary to obtain a satisfactory result.

REFERENCES

1. Parsons TA. The snapping scapula and subscapular exostoses. *J Bone Joint Surg Br* 1973;55:345-349.

2. Milch H. Partial scapulectomy for snapping of the scapula. *J Bone Joint Surg Am* 1950;32:561-566.
3. Ciullo JV. Subscapular bursitis: Treatment of "snapping scapula" or "washerboard syndrome." *Arthroscopy* 1992;8:412-413.
4. Milch H. Snapping scapula. *Clin Orthop* 1961;20:139-150.
5. McClusky GM III, Bigliani LU. Surgical management of refractory scapulothoracic bursitis. *Orthop Trans* 1991;15:801.
6. Wiater JM, Freehill MQ, Levine WN, Flatow EL, Bigliani LU. The operative treatment of scapulothoracic bursitis. Poster No. PE328. Presented at the 67th Annual Meeting of the American Academy of Orthopaedic Surgeons, Orlando, FL, March 2000.
7. Cameron HU. Snapping scapulae: A report of three cases. *Eur J Rheumatol Inflamm* 1984;7:66-67.
8. Richards RR, McKee MD. Treatment of painful scapulothoracic crepitus by resection of the superomedial angle of the scapula: A report of three cases. *Clin Orthop Relat Res* 1989; 111-116.
9. Stirzak AM, Cowen MH. The snapping scapula syndrome: A case report. *J Bone Joint Surg Am* 1982;64:941-942.
10. Harper GD, McIlroy S, Bayley JIL, Calvert PT. Arthroscopic partial resection of the scapula for snapping scapula: A new technique. *J Shoulder Elbow Surg* 1999;8:53-57.
11. Pavlik A, Ang K, Coghlan J, Bell S. Arthroscopic treatment of painful snapping of the scapula by using a new superior portal. *Arthroscopy* 2003;19:608-612.
12. Ciullo JV, Jones E. Subscapular bursitis: Conservative and endoscopic treatment of "snapping scapula" or "washerboard syndrome." *Orthop Trans* 1992-1993;16:740.
13. Constant CR, Murley AHG. A clinical method of functional assessment of the shoulder. *Clin Orthop Relat Res* 1987:160-167.
14. Mozes G, Bickels J, Ovadia D, Dekel S. The use of three-dimensional computed tomography in evaluating the snapping scapula syndrome. *Orthopaedics* 1999;22:1029-1033.
15. Edelson JG. Variations in the anatomy of the scapula with reference to the snapping scapula. *Clin Orthop Relat Res* 1996: 111-115.
16. Lehtinen JT, Tetreault P, Warner JP. Arthroscopic management of painful and stiff scapulothoracic articulation. *Arthroscopy* 2003;19:1-4.
17. Chan BK, Chakrabarti AJ, Bell SN. An alternative portal for scapulothoracic arthroscopy. *J Shoulder Elbow Surg* 2000;11: 235-8.
18. Kuhn JE, Plancher KD, Hawkins RJ. Symptomatic scapulothoracic crepitus and bursitis. *J Am Acad Orthop Surg* 1998; 6:267-273.
19. Carlson HL, Haig AJ, Stewart DC. Snapping scapula syndrome: Three case reports and an analysis of the literature. *Arch Phys Med Rehabil* 1997;78:506-511.